

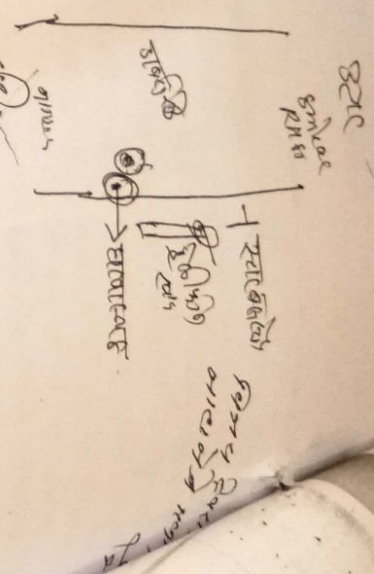
[illegible]

21.23191
78.91806

55

55

55



10. Description of physical evidence from the scene of crime for the property recovers/seized for the purpose of investigation.
Investigation:
न्यायकर्म प्रत्यक्ष पुरावा म्हणून गुरुत्वाच्या जागेवरून मिळविलेल्या / वाचू लागलेल्या वस्तू

11. Date and Time of Panchanama
पदनाम पदनामाची वेळ दिनांक 25/04/20

वेळ 12:19:00 ते 13:30 पर्यंत

12. Name of Panchas
पंचाची नावे

Signature of Panchas
पंचाच्या सह्या

1. पदनाम पदनामाची वेळ दिनांक 25/04/20
पदनाम पदनामाची वेळ दिनांक 25/04/20

Signature

2. पदनाम पदनामाची वेळ दिनांक 25/04/20
पदनाम पदनामाची वेळ दिनांक 25/04/20

Signature

Date
दिनांक 25/04/20

Name and Signature of Investigation officer
न्यायकर्म अमलदारानी मही
Name
नाम 25/04/20
Rank
पदनाम 25/04/20
पोलीस स्टेशन-कळमेरवा, जिल्हा-नागपूर (ग्रामीण)

मकामुना (ओ-५८)-३-२०१८-१,००० रु./२०० पा.-पीपु

स्थानांतरण नमुना

ना. वै. १२१ म.
C.M. 121 म.

प्रभारी वैद्यकीय अधिकारी,

RH Karmahar

प्रभारी वैद्यकीय अधिकारी,

GMC / GMC Nagar

पुढील रुग्णाला कृपया दाखल करून घ्यावे-

रुग्णालय पोल्याकडे

रुग्णाचे नाव-

Bhegvan Miso

70th

वय व स्त्री किंवा पुरुष-

75 year male

रोगनिदान-

RHS Head injury laceration on the right eye
Probably in moving right leg.

दिनांक-

18/6/2019 at 1.30 pm

सही

Medical officer

टीप.-जेव्हा रुग्णाला दाखल करण्यात येते तेव्हा रुग्णालयाच्या वैद्यकीय अधिकार्याच्या स्वाक्षरीत रुग्णाचे वैद्यकीय अधिका-यास अधिसूचित करावे.

RHS
Dr. T. T. G. S. S. S.
Dr. T. T. G. S. S. S.



CENTRAL INDIA'S ONLY HOSPITAL CERTIFIED WITH NABH
 ISO 9001:2008 QMS, ISO 14001 EMS, GHSA 18001:2007 NABL

Certificate No. 1

patient Name
 Address
 Mob. No.
 IP. No.
 Adm. Date
 Ward Info.

Legal Case
 Treating Doctor
 Consultant Doctor

Discharge Summary

: Mr. Bhagwanji Misal [72 Yr /M] UHID:515818062019
 : Yerla Fetri Katol Nagpur, Nagpur, Maharashtra
 : 9049980931
 : IPD.19-20-1044
 : 18-06-2019 03:21PM
 : BED 15/ROOM 202/MALE
 : GENERAL WARD
 : MLC No: 109/19, MLC Consultant: Dr. Ninad Gawande
 : Dr. Sameer Paltewar (MS, MCh (Neurosurgeon))
 : Dr. Gaurav Agarwal (MBBS, MS(ENT),DNB (Oto-Rhino-Laryngology))

Dept./Speciality
 Discharge Date

: NEURO_SURGERY
 : 24-06-2019 10:56 AM

Diagnosis

RTA WITH HEAD INJURY S/O (CEREBRAL CONTUSION) (MULTIPLE FACIAL FRACTURES)
 MULTIPLE FACIAL INJURIES - S09.93
 COMMUNUTED INTRA ARTICULAR FRACTURE OF PROXIMAL END OF TIBIA WITHOUT ANY PERIPHERAL
 NEUROVASCULAR DEFICIT - S82.102A
 SUTURED LW ABOVE RIGHT EYEBROW - S01.111
 KNOWN CASE OF HYPERTENSION - I10.0

Presenting Complaints

This patient was admitted with alleged history of road traffic accident on 18/06/2019 at about 01:00pm at Near Kalmeshwar Bus Stop, Katol Road, Nagpur. Alleged history of patient was walking on road side dashed by two wheeler sustained injury occurred. Patient was primarily treated at R.H. Kalmeshwar. Now brought by relatives to MIMS with history of lacerated wound above right eye brow and right side of face, swelling around right eye, unable to open, blunt trauma to right knee, restriction of movement, abrasion of left leg.

Evaluation And Management

Admitted for evaluation and management.

Examination & vitals

Examination on Admission : 18-06-2019 03:21 PM

Temp : 98.4 Degree F

Pulse : 94 /min

SPO2 : 98 %

RR : 24 /min

BP : 130/80 mmHg

General Condition - Not satisfactory

CVS - Hear Sound : S1S2 Normal

P/Abdomen - Soft, Non Tender

Note - All the post-traumatic injuries present over patient's body have been enumerated in detail in the injury report

Respiratory System - AE II BL

CNS - Spontaneous eye opening

Oriented

Obeys

Pupils : B/L NSRL

GCS : E4M6V5- 15/15



11/07/2019
10.8.2019



**INJURY REPORT
(FORENSIC MEDICAL REPORT)**

To,
The Investigating Officer
Police Station: Kalmeshwar, Nagpur Rural

Total 3 pages

Date: 02/08/2020

Outward No: MLCAR/109/19

Reference: Your letter outward no: 3016/19 dated: 30/07/2020 received on 01/08/2020

Acc. No. 292/19

under sec. 279, 337 IPC r/w 184 MVA

With reference to your letter, I am forwarding herewith the injury report of:

Full Name of the Injured: Mr. BHAGWANJI ZILBAJI MISAL

Age about: 75 yrs

Resident of: Yerla, The Katol, Dist Nagpur

Sex: Male

Hospital I.P. No: 19-20-1044

M.L.C No: 109/19

Medicolegal Diagnosis: RTA with Facial Fractures with Fracture Right Knee.

Team of Consultants:
Dr. Ninad Gawande (Medico-Legal Incharge)
Dr. Anirudha Wargantiwar (Ortho-Surgeon)
Dr. Sameer Patilwar (Ortho-Surgeon)

Date & Time of Admission: 18/06/2019 at 3 20 pm

Date & Time of Discharge: 24/06/2019 at 11 30 am

Patient Brought By: - Mr. Manoj Misal (son)

History of the case in short (as narrated by patient and accomplice) -
H/o RTA on 18/06/2019 at about 1.00 pm near Kalmeshwar Bus stop area, Kalmeshwar. Alleged history of dash by a 2-wheeler while patient was walking along road-side, resulting in injuries. Patient was initially taken to Govt. Hospital, Kalmeshwar and was then shifted to MIMS for further treatment and management.

Condition of patient on admission:
Patient brought in conscious state with complaints of painful restricted movements of right lower limb and multiple facial injuries.

Dr. N. B. Gawande
M.D. Incharge
Medical Institute of Medical Sciences
Nagpur

MLC No. 109/19

Mr. Bhagwan Misal